



Innovation in the surgical technique for prominent ears: A method to prevent recurrence

Jessie Ball T.^{a,*} , Carlos Giugliano V.^b 

^a Resident of Pediatric Surgery, Faculty of Medicine, Universidad del Desarrollo, Santiago, Chile

^b Department of Plastic Surgery, Surgery Service, Clínica Alemana de Santiago, Chile

ARTICLE INFO

Keywords:

Plastic surgery
Modified otoplasty
Prominent ears

ABSTRACT

Background: Prominent ears, a common congenital auricular deformity, can have significant psychosocial consequences. While several surgical techniques exist, recurrence remains a major challenge. This study evaluates a technical modification designed to reduce cartilage memory and minimize recurrence.

Methods: A retrospective analysis was conducted on 70 patients who underwent otoplasty at Clínica Alemana in Santiago, Chile, between 2017 and 2024. The surgical technique combined traditional Mustardé and Furnas methods with targeted cartilage incisions guided by anterior methylene blue tattoos, aimed at weakening cartilage memory. Outcomes were assessed using the Strasser scale and complication rates were analyzed.

Results: 70 patients were included in this series. The average patient age was 9 years. Complications occurred in 20 % of cases, primarily suture exposure (14.3 %) and minor infections (2.8 %), all managed without reoperation. No recurrences were observed over a mean follow-up of 12 months. In 21 patients evaluated with the Strasser scale, the average score was 2, indicating good aesthetic outcomes.

Conclusion: The described technical modification is a safe, reproducible approach that effectively prevents recurrence of auricular prominence. By addressing cartilage memory, the technique enhances long-term aesthetic results and reduces the need for reoperation.

Introduction

Prominent ears are a type of congenital auricular malformation characterized by the absence of the antihelical fold and a deficiency of the scapha, which may or may not be associated with an enlarged concha. This results in an abnormal protrusion of the auricle. This malformation affects approximately 5 % of the population and has significant psychosocial consequences for patients [1,2].

Multiple surgical techniques have been described for the correction of this condition, but none has proven to be universally effective. The most widely used is Mustardé's technique to recreate the antihelical fold [3]. Furnas later described the fixation of the auricle to the mastoid [2, 4]. Skoog also proposed a modification of Mustardé's technique, in which sutures are placed through the perichondrium instead of the cartilage [5]. To manage the cartilage's memory, techniques such as cartilage weakening using diamond burrs—particularly in thicker cartilage—or partial resections have been described [6–8].

Otoplasty is a procedure with few complications, which may include keloids, bleeding, suture extrusion, unsatisfactory cosmetic outcomes,

and asymmetry. One of the most important issues for the surgeon to address is the recurrence of the deformity, which implies a poor aesthetic result and the need for reoperation [9,10].

In this paper, we describe a modification to the standard otoplasty technique with the aim of reducing the risk of recurrence of this condition, along with an evaluation of our cosmetic outcomes in patients operated at Clínica Alemana in Santiago, Chile.

Materials and methods

A retrospective analysis was conducted including all consecutive patients who underwent surgery for prominent ears at Clínica Alemana in Santiago between 2017 and 2024. All surgeries were performed by the same surgeon (second author of this article).

This study has approval from our Ethics Committee and informed consent was obtained for all patients included.

Outcomes were evaluated using the Strasser scale [11], which assesses aesthetic results based on five parameters: malposition, distortion, asymmetry, contour deformity, and scarring. Each parameter is

* Corresponding author at: Av. Manquehue Norte. 1410, Vitacura, Región Metropolitana, Chile.

E-mail address: j.ballt@udd.cl (J. Ball T.).

scored as *perfect*, *noticeable*, *obvious*, or *deforming*, with corresponding point values used to calculate a total score. A score between 0 and 4 indicates a good result, between 5 and 14, a mediocre result, and greater than 15 points indicates a poor result. This scale was applied by four surgeons external to the team, who evaluated the patients' photographs and assigned a score to each image. The individual scores were then averaged to obtain the final score.

The surgical technique used in this group of patients is described below. Under general anesthesia, and following infiltration with a vasoconstrictor, an incision is made in the retroauricular skin crease. Skin excision is not routinely performed, and is only considered in patients with prominent lobes. In such cases, a diamond-shaped excision is performed in severe cases, or a hemi-diamond excision in moderate cases, to correct this specific defect.

Retroauricular dissection is then carried out in the supraperiosteal plane over the mastoid area, with particular care to avoid injury to the external auditory canal. A fine scissors subcutaneous retroauricular dissection is also performed. The absent or underdeveloped antihelical fold is then marked and recreated using hypodermic needles.

To manage cartilage memory, areas of greatest stiffness are identified during the formation of the new antihelical folds. These areas undergo weakening of the cartilaginous structure, continuing until a noticeable reduction in tissue resistance is observed.

To achieve this, methylene blue is used to tattoo the anterior surface of the auricle along the junction between the conchal bowl and the newly defined antihelix (Fig. 1). On the posterior side, cartilage incisions are made along the previously tattooed zones (Fig. 2).

This procedure is repeated in the triangular fossa to create the new fold of the posterior crus of the antihelix, in the same manner as described above.

Subsequently, U-shaped sutures are placed through the cartilage at the newly created antihelical folds using the technique described by Mustardé [3], with four clear 4-0 nylon sutures distributed along the body of the antihelix and the posterior crus. During this step, reduced resistance of the cartilage is confirmed when recreating the folds.

Each of these 4-0 nylon sutures used to reconstruct the new folds is also employed to fix the auricle to the periosteum of the mastoid bone, setting the distance between the auricle and the mastoid plane to between 1 and 1.5 cm.

Finally, the skin incision is closed with a continuous 5-0 fast-absorbing polyglycolic acid suture, eliminating the need for suture removal postoperatively.

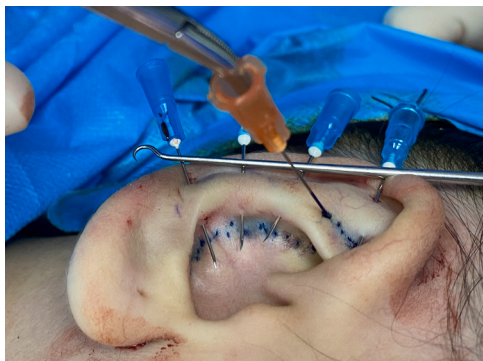


Fig. 1. The creation of the new antihelical fold is shown, as defined by hypodermic needles. Additionally, the methylene blue tattoo is visible at the junction between the conchal bowl and the antihelix, as well as in the triangular fossa and the posterior crus of the antihelix. These marks indicate areas of greater tissue resistance or cartilage memory, which are then incised from the posterior side using a scalpel.

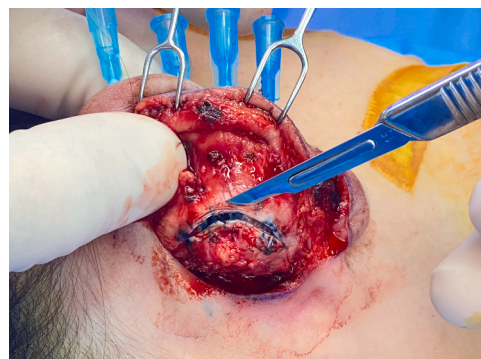

Fig. 2. On the posterior surface of the auricle, at the level of the conchal bowl, the incision is seen precisely at the area previously tattooed on the anterior surface. This serves to weaken the cartilaginous structure between the concha and the antihelix and to reduce its tissular memory.

Results

A total of 70 patients were included in the study. The average age was 9 years, ranging from 3 to 18 years. Of the total, 30 were male and 40 were female.

Regarding complications, 14 cases were recorded, including 10 patients with suture material exposure, 2 patients with local infection, 1 patient with a keloid and 1 patient with minor wound dehiscence. No patient experienced a recurrence during long-term follow-up, with an average follow-up of 1 year, ranging from 6 months to 2 years.

Analyzing the data the rate of early complications was 4 %, the rate of late complications was 16 %. The overall complication rate was 20 %. None of these complications required surgical reintervention, and none resulted in recurrence of auricular prominence. All complications responded well to specific, non-surgical treatment.

Aesthetic results were evaluated using the Strasser scale. A randomly selected representative sample of 21 patients was used for the application of the scale, all photos were taken at least 6 months after the surgery. The results were an average score of 2 points, which corresponds to a good result according to the classification (Fig. 3).

Discussion

In this study, we present a modification to the classic technique used in the surgical treatment of prominent ears. We apply the principles of Mustardé and Furnas [3,4] for antihelix reconstruction and auricle fixation to the mastoid, but for us, the most relevant component is eliminating cartilage memory through incisions, in an effort to avoid the risk of recurrence.

Among the innovative aspects described in this technique, the first is the methylene blue tattoo along the anterior junction between the conchal bowl and the newly created antihelix. This step allows us to mark and visualize, from the posterior aspect of the ear, the area where stress concentrates on the cartilage — a potential site for recurrence.

By making incisions in this marked area, we effectively separate the concha from the antihelix, thereby controlling the cartilage's memory in this region. These incisions disrupt the circumferential tensile forces of the cartilage by introducing a structural discontinuity between the concha and the neoantihelix created, thereby abolishing the tissue memory in this region. This approach resulted in a 0 % recurrence rate in our experience over the study period. Unlike the original Mustardé technique, these incisions overcome the cartilage's natural tendency to revert to its original position, reducing tension on the sutures placed to form the new antihelix and minimizing the likelihood of the ear returning to its preoperative shape.

These cartilage-relieving incisions are not continuous; we intentionally leave cartilaginous bridges to avoid creating steps or sharp

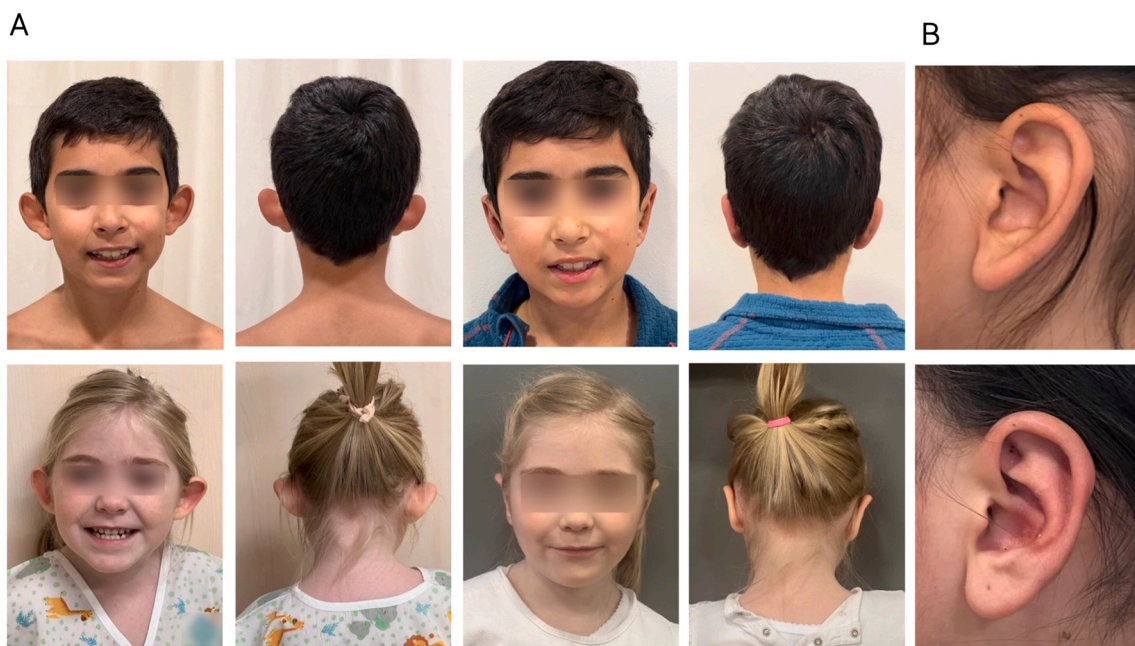

Fig. 3. A. Pre- and postoperative comparison of prominent ears treated with the described technique. Strasser score: 2 points.

B. Long-term outcome of the reconstructed neoantihelix. The goal is to achieve a natural-appearing antihelix without visible indicators of surgical reconstruction.

edges between segments, which could become visible through the anterior skin of the concha and result in an inadequate cosmetic outcome. We prefer this technique over cartilage resection, as resections carry a higher risk of distorting the ear's natural anatomy.

Regarding suture material, we have consistently used non-absorbable, colorless 4-0 nylon, as suggested by Mustardé [3].

Complications reported in the literature are diverse. They can be classified as early complications when they appear within the first 14 days and late complications when they appear after 14 days. Among early complications we can have wound infection, hematoma, bleeding, skin necrosis and wound dehiscence.

On the other hand late complications include hypertrophic scarring, asymmetry, hypersensitivity, suture exposure, and unsatisfactory cosmetic results such as overcorrection or recurrence [9]. Reported complication rates in the literature vary, early complications: 3 % to 17 %, late complications: 6 % to 40 % [9]. As for recurrence the reported incidence varies from 6 % to 12 % [10].

In our series, the main complications were suture exposure, hypertrophic scarring, and local infection. When comparing our results with the literature, we observed a similar or even lower overall complication rate, with a 0 % recurrence rate in this cohort. In our prior 10-year review, recurrence rates ranged between 3 % and 5 % using the classic Mustardé and Furnas techniques, without any action over the cartilage itself to reduce its ticular memory. Recurrence is undesirable from a surgical standpoint, as it implies a need for reoperation, with all the associated psychosocial implications.

Regarding cosmetic outcomes, we observed adequate Strasser scores, with an average of 2 points. In the literature, few studies objectively assess the aesthetic results of this surgery. One review mentions cosmetic evaluation, but it is subjective and conducted by the same surgical team [12]. The use of the Strasser scale provides a validated, objective international standard for outcome evaluation.

The psychosocial impact of this surgery is highly significant and has been measured in various studies. Patients report improvements in self-esteem, self-image, personal satisfaction, and reduced rates of depression, with an overall positive impact on quality of life [13]. In children, this also greatly affects their parents, who may experience guilt when their child is subject to bullying due to ear appearance.

The goal of this surgery, beyond achieving an adequate, symmetric, and natural cosmetic result, should include ensuring that the surgical intervention is not visibly evident.

There are some limitations in this study, which include the retrospective design, the single-surgeon series and the possibility that recurrence occurs later in time, which would not appear in our 12 month mean follow-up. Nevertheless we consider that the most important period in the scarring process is in the first 6 months after the procedure, so we do not expect any major recurrences after the 12 month period.

Conclusion

The proposed technical modification aimed at weakening the tissue memory of auricular cartilage in cases of prominent ears is reproducible and has proven to be effective in this series, preventing recurrence (0 % in this series) and, consequently, the need for surgical reintervention.

CRediT authorship contribution statement

Jessie Ball T.: Writing – original draft, Methodology, Formal analysis, Data curation, Conceptualization. **Carlos Giugliano V.:** Conceptualization, Methodology, Resources, Validation, Writing – review & editing.

Declaration of competing interest

The authors declare that they have no known competing financial interests or personal relationships that could have appeared to influence the work reported in this paper.

References

- [1] SS Pawar, CA Koch, C Murakami, Treatment of prominent ears and otoplasty: A contemporary review, *JAMA Facial Plast Surg* 17 (2015) 449–454, <https://doi.org/10.1001/jamafacial.2015.0783>.
- [2] I Lese, M Aldabbas, AS Mazed, et al., Lop ear to conchal Microtia: An algorithmic surgical approach, *Ann Plast Surg* 88 (2022) 188–194, <https://doi.org/10.1097/SAP.0000000000002888>.
- [3] JC. Mustarde, The correction of prominent ears using simple mattress sutures, *Br J Plast Surg* 16 (1963) 170–180, [https://doi.org/10.1016/s0007-1226\(63\)80100-9](https://doi.org/10.1016/s0007-1226(63)80100-9).

- [4] DW. Furnas, Correction of prominent ears by concha-mastoid sutures, *Plast Reconstr Surg* 42 (1968) 189–193.
- [5] T. Skoog. *Plastic Surgery; New Methods and Refinements*, Saunders, Philadelphia, 1974.
- [6] D Obadia, J Quilichini, V Hunsinger, et al., Cartilage splitting without stitches: Technique and outcomes, *JAMA Facial Plast Surg* 15 (2013) 428–433, <https://doi.org/10.1001/jamafacial.2013.326>.
- [7] A Gantous, A-J Tasman, JC Neves, Management of the prominent ear, *Facial Plast Surg Clin North Am* 26 (2018) 181–192, <https://doi.org/10.1016/j.fsc.2017.12.010>.
- [8] SJ Stenstrom, J Heftner, The stenstrom otoplasty, *Clin Plast Surg* 5 (1978) 465–470, [https://doi.org/10.1016/s0094-1298\(20\)32151-9](https://doi.org/10.1016/s0094-1298(20)32151-9).
- [9] GC Limandjaja, CC Breugem, AB Mink van der Molen, et al., Complications of otoplasty: a literature review, *J Plast Reconstr Aesthet Surg* 62 (2009) 19–27, <https://doi.org/10.1016/j.bjps.2008.06.043>.
- [10] EB Handler, T Song, C Shih, Complications of otoplasty, *Facial Plast Surg Clin North Am* 21 (2013) 653–662, <https://doi.org/10.1016/j.fsc.2013.08.001>.
- [11] EJ. Strasser, An objective grading system for the evaluation of cosmetic surgical results, *Plast Reconstr Surg* 104 (1999) 2282–2285, <https://doi.org/10.1097/00006534-199912000-00058>.
- [12] ML Boroditsky, AC Van Slyke, JS Arneja, Outcomes and complications of the Mustardé otoplasty: A “good-fast-cheap” technique for the prominent ear deformity: A “good-fast-cheap” technique for the prominent ear deformity, *Plast Reconstr Surg Glob Open* 8 (2020) e3103, <https://doi.org/10.1097/GOX.0000000000003103>.
- [13] NA Papadopoulos, R Niehaus, E Keller, et al., The psychologic and psychosocial impact of otoplasty on children and adults, *J Craniofac Surg* 26 (2015) 2309–2314, <https://doi.org/10.1097/SCS.0000000000001990>.